

Definitive histologic diagnosis on prostate biopsies in 3 hours

L. Nava\$, M. Freschi @, C.Dogliani @, E. Scapaticci\$, A. Losa\$, M. Riva\$, P. Rigatti\$, and G. Guazzoni\$
 \$\$S. Raffaele-Turro, Department of Urology. Vita-Salute San Raffaele University, Milan – Italy
 @S. Raffaele-Turro, Department of Pathology. Vita-Salute San Raffaele University, Milan – Italy

INTRODUCTION & OBJECTIVES

Microwave-based devices allow ultra-rapid histoprocessing of biptic specimens, surgical tissue blocks and whole organs. The aim of this study was to prospectively evaluate the efficacy and reproducibility of quickly processing prostate core needle biopsies with RHS1[®], an automated microwave-vacuum processor.


MATERIAL & METHODS

From July 2004 to July 2006 a total of 688 consecutive transrectal ultrasound-guided prostate biopsies were performed for Pca detection in men with PSA levels between 2.5 and 14 ng/ml. The biopsies (mean core number 20, range 14-24) were stretched between two sponges in tissue cassettes, fixed in formalin 4% solution, processed with RHS1[®] (xylene-free), embedded in paraffin, cut at 3 μ and then stained with Hematoxylin-Eosin.

RHS1[®] is an automated microwave vacuum histoprocessor that combines uniform microwave irradiation with precise computer control of power, time, temperature, vacuum and pressure. RHS1[®] uses a 1-step dehydrating/clearing mixture reagent and eliminates the use of hazardous reagents, such as xylene. Under microwave irradiation the reagent ultra-rapidly and simultaneously eliminates, as a single step, water and lipids from tissue, ready for wax impregnation. RHS1[®] is a flexible device holding up to 110 cassettes per run.

Processing time, as well as time to final histological report, detection rate and percentage of additional evaluations required were recorded; those results were prospectively compared with those registered in a contemporaneous series of 563 prostate biopsies performed in a similar series of patients, with the same sample technique, in the same period, but processed with the traditional method. Histopathological evaluations were performed by a single pathologist and underwent a subsequent intradepartmental review.

Methods: RHS1[®]



The RHS-1[®]
Microwave Vacuum
Histoprocessor

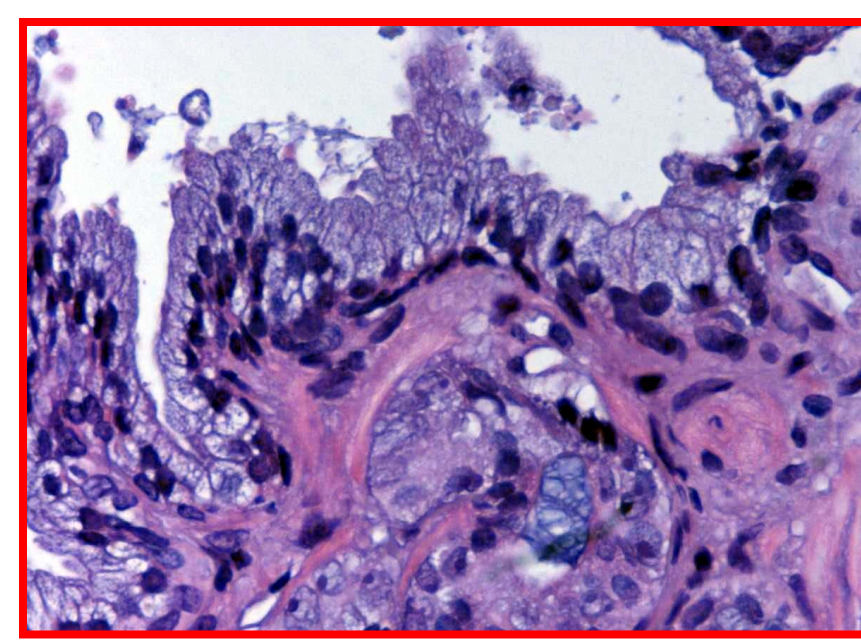
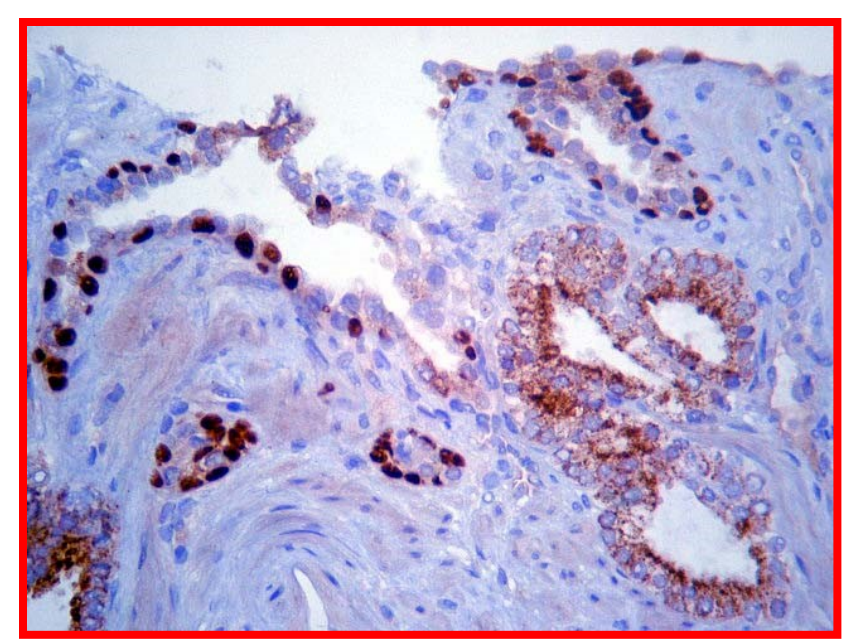
Combines uniform MW irradiation with precise computer control of power, time, temperature, vacuum and pressure.

Results: overall detection rate

| | RHS1 [®] processed biopsies | traditionally processed biopsies |
|-------|--|--|
| PCA | 39.7% | 41% |
| HGPIN | 20% | 18.6% |
| ASAP | 2% | 3% |

Both groups received a comparable quality evaluation by different pathologists. No differences in core lengths were recorded in both groups.

Results: histopathology

RHS1[®] processed biopsy:
Magnification in H.E. with one
neoplastic gland at hour 6 and
normal glands on the top

RHS1[®] processed biopsy:
Double immunostain to
p63 + racemase
(AMACR)

Results: turnaround times

| | RHS1 [®] processed biopsies | traditionally processed biopsies |
|---------------------------------|--|--|
| processing time | 1 h 15' | 14h |
| time to definitive diagnosis | 3 h 10' * (145' – 260') | 24 h |

* in 27 patients additional immunohistochemical evaluation was needed

RESULTS

The overall detection rate for both groups (RHS1[®] - processed biopsies vs. biopsies traditionally processed) was similar: 39.7% of Pca vs 41%, 20% of HGPIN vs. 18.6% , 2% of ASAP vs.3%. A comparable quality evaluation was given by the pathologist for both groups, confirmed at an intradepartmental review. No differences in core lengths were recorded pre- and post-processing. The automatic processing time was 75 minutes (RHS1[®] - processed biopsies) vs. 14 hours, whereas the time to definitive diagnosis was 190 minutes (range 145-260) vs. 24 hours. RHS1[®] resulted reliable and user friendly. A quick diagnosis was performed in 661/ 688 pts (96%); in 27 pts additional immunohistochemical evaluations were successively performed without any modification of routinely used methods. In the same day all patients could conclude the diagnostic and staging process.

RESULTS: HISTOPATHOLOGY

RHS1[®] processed biopsies revealed:

- Core lengths comparable to traditionally processed biopsies
- Excellent cutting properties
- Excellent staining, histochemistry and immunohistochemistry properties
- Optimal preservation of tissue architecture
- Uniform cytomorphology
- Quality evaluation comparable to traditionally processed biopsies
- Possible DNA and RNA extraction for molecular biology techniques

CONCLUSIONS

The two years experience confirms the validity of this new automated, microwave-based, vacuum device to process in a short time prostate biopsies. RHS1[®] resulted at least as effective as the traditional processing method, and could guarantee a new time-effective standard to spare time, costs and stress for the patient; as recently confirmed, in patients dealing with prostate cancer, the peak of anxiety level is reached around the time of biopsy.

RHS1[®] allows all the routine staining, histochemistry, immunohistochemistry and molecular biology techniques. RHS1[®] decreases turnaround times. Being a xylene-free method, handling of the specimens is simplified and safer.

RHS1[®] allows a better quality of service with a one-day diagnosis enhancing patient care.

REFERENCES

- (1) F.Visinoni, J.Milios, A.S.-Y.Leong, M.E.Boon, L.P.Kok, F.Malcangi: Ultra-Rapid Microwave/Variable Pressure-Induced Histoprocessing: Description of a New Tissue Processor. The Journal of Histotechnology/ Vol.21, No.3/September 1998
- (2) A.S.-Y.Leong, D.Price: Incorporation of microwave tissue processing into a routine pathology laboratory: impact on turnaround times and laboratory work patterns. Pathology (August 2004) 36(4) pp.1-4
- (3) S.Bennet: Fast but not furious. Pathology in Practice, Vol.5, Issue1/ February 2004, pp.38-39
- (4) A.S.-Y.Leong: Microwave Technology for Light Microscopy and Ultrastructural Studies. 2005:Amarin Printing and Publishing Public Company Ltd